

# Trigeminal neuralgia secondary to compression of giant quadrigeminal cistern arachnoid cyst in an adult: Case report and review of the literature

 Hüseyin Berk Benek,  Hakan Yılmaz,  Alper Tabanlı,  Emrah Akçay,  Alaattin Yurt

Department of Neurosurgery, Health Sciences University, İzmir Bozyaka Training and Research Hospital, İzmir, Türkiye

## SUMMARY

A quadrigeminal cistern arachnoid cyst is an extremely rare cause of trigeminal neuralgia in adulthood. This report presents the fourth case in the literature of trigeminal neuralgia caused by a giant quadrigeminal cistern arachnoid cyst. A 52-year-old woman presented with a 3-month history of cerebellar ataxia and vertigo. She had a 2-year history of trigeminal neuralgia that was unresponsive to medical therapy. Neuroimaging studies revealed a cystic lesion in the quadrigeminal cistern associated with hydrocephalic enlargement. Using an infratentorial supracerebellar approach, neuroendoscope-assisted decompression and fenestration of the cyst were performed. Postoperatively, the patient was pain-free and able to walk unaided without symptoms of ataxia.

**Keywords:** Arachnoid cyst; ataxia; hydrocephalus; quadrigeminal cistern; trigeminal neuralgia.

## Introduction

Arachnoid cysts (ACs) are cerebrospinal fluid (CSF) collections surrounded by an arachnoid membrane. ACs are usually asymptomatic but may cause symptoms with increased intracranial pressure. ACs in the quadrigeminal cistern have been rarely reported and are mostly seen in infants and adolescents.<sup>[1–5]</sup> In this report, we present a giant arachnoid cyst in the quadrigeminal cistern in an adult, causing trigeminal neuralgia and ataxia due to compression and displacement of the brainstem. To the best of our knowledge, it is the fourth case in the literature of trigeminal neuralgia caused by a quadrigeminal cistern arachnoid cyst.<sup>[6–8]</sup>

## Case Report

A 52-year-old woman presented with a 3-month history of cerebellar ataxia and vertigo. The patient could not walk alone without the support of another person.

She had a 2-year history of trigeminal neuralgia unresponsive to medical therapy. She experienced episodic pain in the second division of the left trigeminal nerve, with a trigger point in the mouth. On physical examination, she had bilateral horizontal nystagmus and papilledema. CT revealed a large cystic isodense lesion with CSF in the area of the quadrigeminal cistern, causing severe compression on the aqueduct of Sylvius, posterior third ventricle, and mesencephalon from the left lateral side, associated with hydrocephalic enlargement of the third and lateral ventricles (Fig. 1a). MRI revealed a 50×25 mm quadrigeminal cystic lesion, isointense with CSF on T1- and T2-weighted images, extending from the superior to the anterior of the cerebellum, displacing the pons anteriorly and superiorly. There was no restricted diffusion within the cyst and no contrast enhancement (Fig. 1b, c). These neuroimaging studies suggested that this lesion was an arachnoid cyst of the quadrigeminal cistern causing trigeminal neuralgia.

Submitted: 03.08.2022 Received: 20.12.2022 Accepted: 05.04.2023 Available online: 04.07.2025

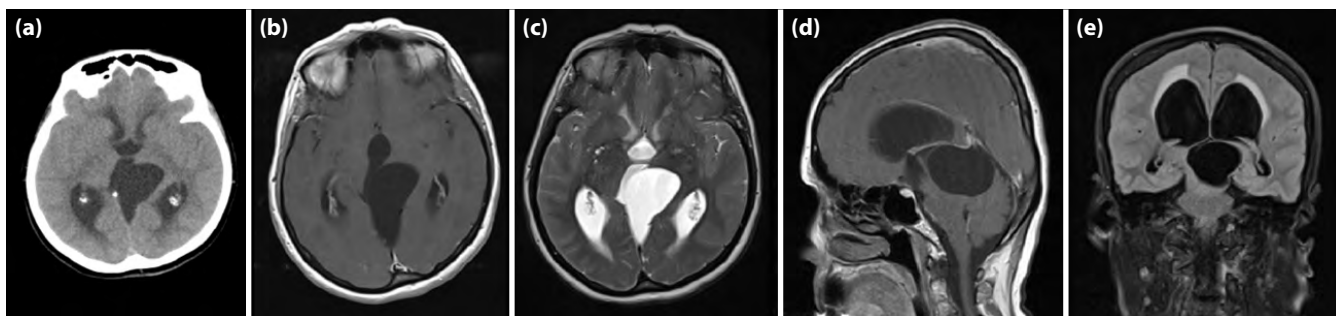
**Correspondence:** Dr. Hüseyin Berk Benek. Sağlık Bilimleri Üniversitesi, İzmir Bozyaka Eğitim ve Araştırma Hastanesi, Beyin ve Sinir Cerrahisi Kliniği, İzmir, Türkiye.  
**Phone:** +90 - 532 - 476 94 81 **e-mail:** benekberk@gmail.com



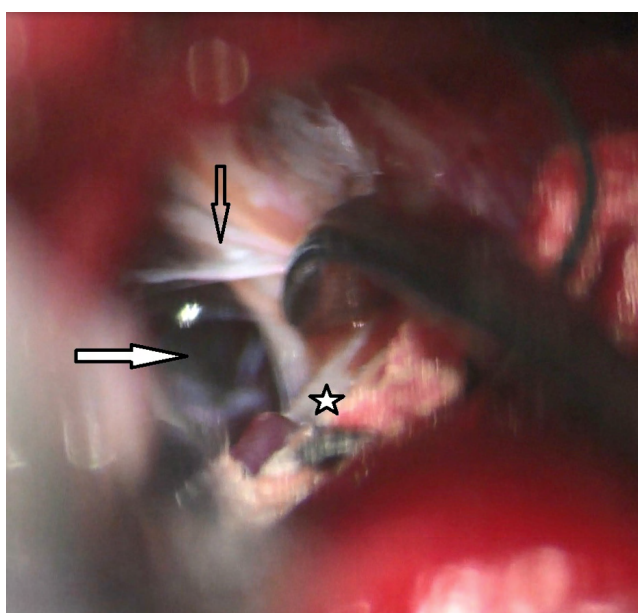
OPEN ACCESS

This is an open access article under the CC BY-NC license (<http://creativecommons.org/licenses/by-nc/4.0/>).



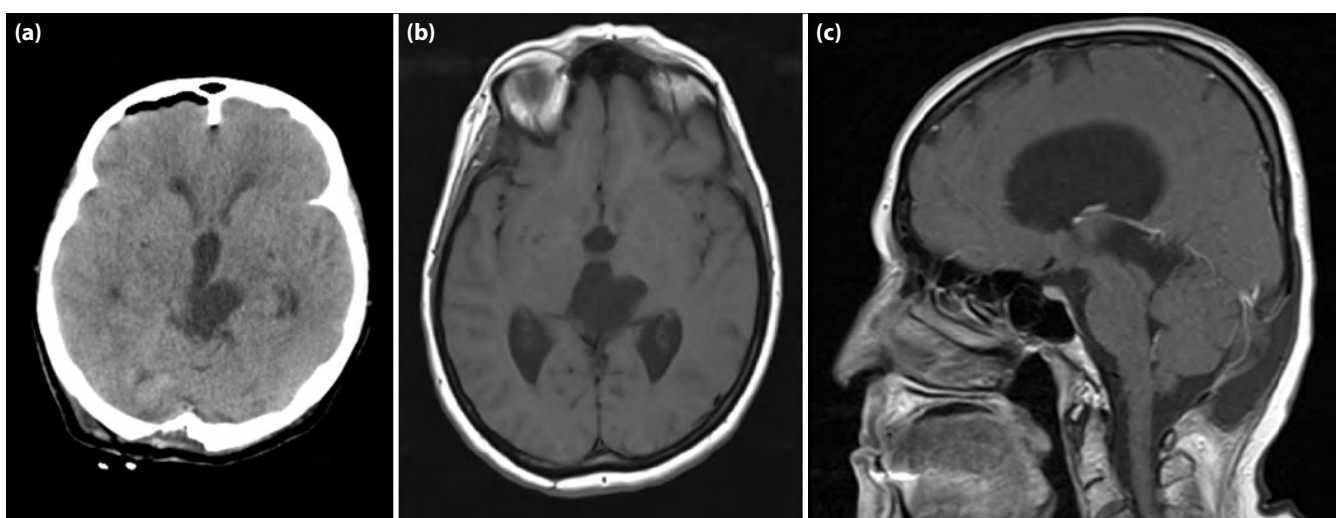


**Figure 1.** Preoperative computed tomography scan demonstrating an isodense lesion with CSF in the area of quadrigeminal cistern (a). Axial T1- weighted (b), T2- weighted (c), sagittal (d), coronal (e) MRI revealed 50x25 mm cystic mass, isointense with CSF on T1- and T2- weighted images, causing severe compression on the aqueduct of Sylvius, posterior third ventricle and mesencephalon from left lateral side, associated with hydrocephalic enlargement of ventricles. extending from superior to the anterior of the cerebellum, displacing the pons anteriorly and superiorly.



**Figure 2.** Intraoperative microscopic view of the arachnoid cyst in the quadrigeminal cistern after infratentorial supracerebellar approach. White arrow: arachnoid cyst, black arrow: membrane of the arachnoid cyst, star: cerebellum.

A suboccipital paramedian incision was performed in the prone position. Using an infratentorial supracerebellar approach, we reached the arachnoid cyst in the quadrigeminal cistern (Fig. 2). The cyst was drained of 20 mL fluid with wide resection of the wall of the arachnoid cyst. Neuroendoscopically assisted decompression and fenestration of the cyst to the cisterns and ventricles were performed with caution regarding the trochlear and trigeminal cranial nerves and the superior cerebellar artery. Histological examination of the cyst wall specimen revealed a diagnosis of arachnoid cyst. Postoperative early CT confirmed a significant dimensional regression (Fig. 3a). Postoperatively, the patient was pain-free without any medical treatment and could walk alone without ataxia symptoms. She was discharged after ten days without any neurological deficits. Follow-up MRI in the twelfth month revealed the cyst size had decreased to 20x15 mm (Fig. 3b, c).



**Figure 3.** Postoperative early CT scan (a), and axial T1- weighted (b), and sagittal MRI (c) twelve months postoperatively showing the cyst size decreased to 20x15 mm.

**Table 1. Quadrigeminal cistern arachnoid cyst cases presenting with trigeminal neuralgia reported in the literature**

Number	Authors	Patient age	Gender	Cyst Location	Side	Treatment
1	Mitsos AP et al. <sup>[6]</sup>	68	Female	Quadrigeminal	Right	Craniotomy
2	Ohnishi YI et al. <sup>[7]</sup>	62	Female	Quadrigeminal	Right	Craniotomy-endoscope
3	Hayashi Y et al. <sup>[8]</sup>	68	Female	Quadrigeminal	Left	Endoscope
4	Benek HB et al. (current report)	52	Female	Quadrigeminal	Left	Craniotomy- endoscope

## Discussion

Quadrigeminal cistern arachnoid cysts in adulthood are extremely rare, with a prevalence of only 2%–2.7% of all arachnoid cysts.<sup>[9]</sup> Infratentorial arachnoid cysts cause early symptoms that result in early diagnosis, unlike supratentorial arachnoid cysts. The symptoms usually depend on the extent of the compression on the cerebellum, brainstem, and aqueduct of Sylvius. Garg et al.<sup>[10]</sup> analyzed 18 patients with quadrigeminal cistern arachnoid cysts for clinical presentation, management, and outcome. They concluded that endoscopic fenestration of the cyst with cystocisternostomy or cystoventriculostomy, when combined with third ventriculostomy, is the procedure of choice for such patients. Deora H. stated that quadrigeminal cistern ACs and associated hydrocephalus can be successfully treated with simple, minimally invasive endoscopic procedures.<sup>[11]</sup> Silva MA et al.<sup>[12]</sup> performed a retrospective analysis of 12 patients treated for QAC and stated that endoscopic fenestration is the most common treatment for QAC, and identifying patients who require initial treatment of hydrocephalus is critically important.

Trigeminal neuralgia, a pathology of vascular compression of the root entry zone of the trigeminal nerve, is the most common neuralgia in adults. While medical therapy is the first-line treatment, microvascular decompression remains the gold standard operative procedure for patients with resistant pain.<sup>[13]</sup> In the present case, the quadrigeminal cistern arachnoid cyst caused severe compression of the mesencephalon and the root entry zone of the left trigeminal nerve. This compression is probably the leading cause of trigeminal neuralgia. Mitsos et al.<sup>[6]</sup> presented the first case in the literature of a quadrigeminal cistern arachnoid cyst causing trigeminal neuralgia. Ohnishi et al.<sup>[7]</sup> reported the second case treated with

neuroendoscopically assisted cyst-cisternal shunting via a small craniotomy. Hayashi et al.<sup>[8]</sup> noted that only five cases of cerebellopontine angle (CPA) arachnoid cysts with trigeminal neuralgia have been reported to date, and all of them have been found to extend into the quadrigeminal cistern, which compressed the trigeminal nerves. Three of the five cases were defined as quadrigeminal arachnoid cysts, and not as CPA arachnoid cysts.<sup>[8]</sup> This current report is the fourth case in the literature (Table 1). The management of quadrigeminal cistern arachnoid cysts is challenging for many neurosurgeons, requiring various fenestration procedures.<sup>[9]</sup> In the present case, we performed ventriculocystocisternostomy for obstructive hydrocephalus due to aqueduct stenosis, which was preoperatively shown by CSF flow MRI. Hydrocephalus regressed after surgery, and the patient did not require ventriculoperitoneal shunting during the follow-up period.

## Conclusion

Compression at the root entry zone of the trigeminal nerve may be caused by pathologies other than vascular compression by an overlying artery. Trigeminal neuralgia can be relieved by endoscope-assisted decompression and fenestration of the cyst.

**Ethics Committee Approval:** This is a single case report, and therefore ethics committee approval was not required in accordance with institutional policies.

**Informed Consent:** Written informed consent was obtained from patients who participated in this study.

**Conflict-of-interest issues regarding the authorship or article:** The authors declare that there is no conflict of interest.

**Financial Disclosure:** The authors have no sources of funding to declare for this manuscript.

**Use of AI for Writing Assistance:** No artificial intelligence was used.

**Authorship Contributions:** Concept – HBB, HY; Design – HBB, AT; Supervision – EA, AY; Resource – HBB, AY; Materials – HBB, HY; Data collection and/or processing – HBB, AT; Analysis and/ or interpretation – HY, EA; Literature review – HY, AT; Writing – HBB, HY; Critical review – EA, AY.

**Peer-review:** Externally peer-reviewed.

## References

- Hayashi N, Endo S, Tsukamoto E, Hohnoki S, Masuoka T, Takaku A. Endoscopic ventriculocystocisternostomy of a quadrigeminal cistern arachnoid cyst. Case report. *J Neurosurg* 1999;90:1125-8. [\[CrossRef\]](#)
- Pagni CA, Canavero S, Vinci V. Left trochlear nerve palsy, unique symptom of an arachnoid cyst of the quadrigeminal plate. Case report. *Acta Neurochir (Wien)* 1990;105:147-9. [\[CrossRef\]](#)
- Spaziante R, Cirillo S, Constans JP, de Divitiis E, Donzelli R, Stella L. Arachnoid cyst of the quadrigeminal cistern. *Neurochirurgia (Stuttg)* 1986;29:117-23. [\[CrossRef\]](#)
- Topsakal C, Kaplan M, Erol F, Cetin H, Ozercan I. Unusual arachnoid cyst of the quadrigeminal cistern in an adult presenting with apneic spells and normal pressure hydrocephalus--case report. *Neurol Med Chir (Tokyo)* 2002;42:44-50. [\[CrossRef\]](#)
- Wakisaka S, Yoneda K, Kitano I, Kinoshita K, Matsuoka S. Arachnoid cyst in the quadrigeminal cistern. *Surg Neurol* 1986;26:52-8. [\[CrossRef\]](#)
- Mitsos AP, Samelis AI, Panteleakou-Sameli HM, Kot-tas GD. Arachnoid cyst of quadrigeminal cistern presenting as trigeminal neuralgia. *Acta Neurochir (Wien)* 2006;148:93-4. [\[CrossRef\]](#)
- Ohnishi YI, Fujimoto Y, Taniguchi M, Tsuzuki T, Taki T. Neuroendoscopically assisted cyst-cisternal shunting for a quadrigeminal arachnoid cyst causing typical trigeminal neuralgia. *Minim Invasive Neurosurg* 2007;50:124-7. [\[CrossRef\]](#)
- Hayashi Y, Takata S, Iizuka H. Endoscopic treatment for arachnoid cyst at the cerebellopontine angle presenting with bilateral trigeminal neuralgia: Case report and literature review. *Interdiscip Neurosurg* 2020;22:100815. [\[CrossRef\]](#)
- Laviv Y, Neto S, Kasper EM. Management of quadrigeminal arachnoid cyst associated with obstructive hydrocephalus: Report on stereotactic ventricular - cystic stenting. *Br J Neurosurg* 2019;33:418-21. [\[CrossRef\]](#)
- Garg K, Tandon V, Sharma S, Suri A, Chandra PS, Kumar R, et al. Quadrigeminal cistern arachnoid cyst: A series of 18 patients and a review of literature. *Br J Neurosurg* 2015;29:70-6. [\[CrossRef\]](#)
- Deora H. Endoscopic management of quadrigeminal arachnoid cyst with neuronavigation guidance. *World Neurosurg* 2022;161:135. [\[CrossRef\]](#)
- Silva MA, Chang H, Weng J, Hernandez NE, Shah AH, Wang S, et al. Surgical management of quadrigeminal cistern arachnoid cysts: Case series and literature review. *J Neurosurg Pediatr* 2022;29:427-34. [\[CrossRef\]](#)
- Spina A, Mortini P, Alemanno F, Houdayer E, Iannaccone S. Trigeminal neuralgia: Toward a multimodal approach. *World Neurosurg* 2017;103:220-30. [\[CrossRef\]](#)